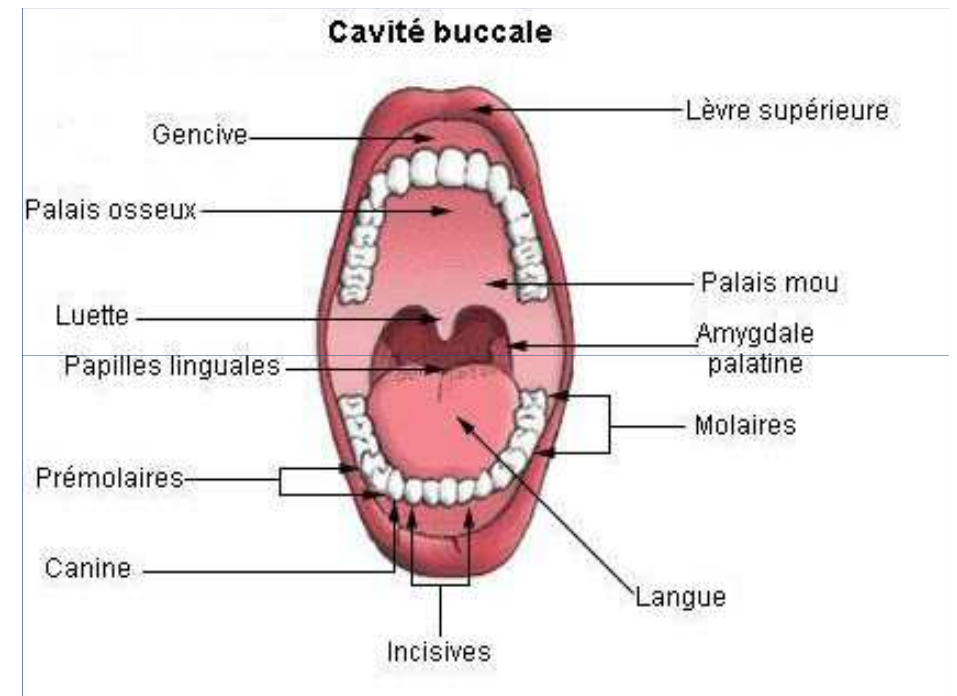
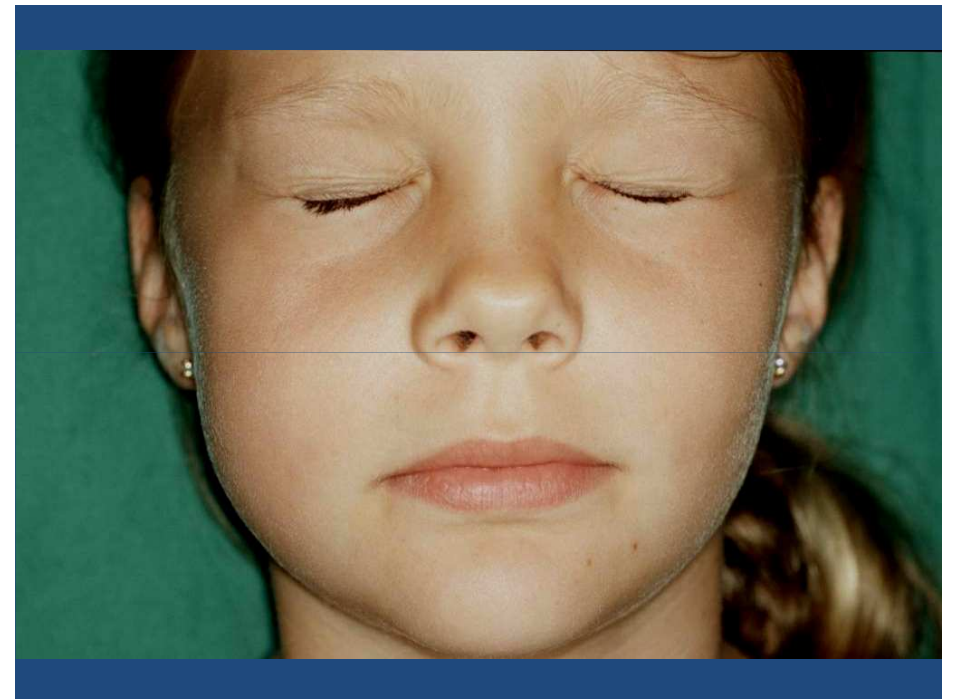
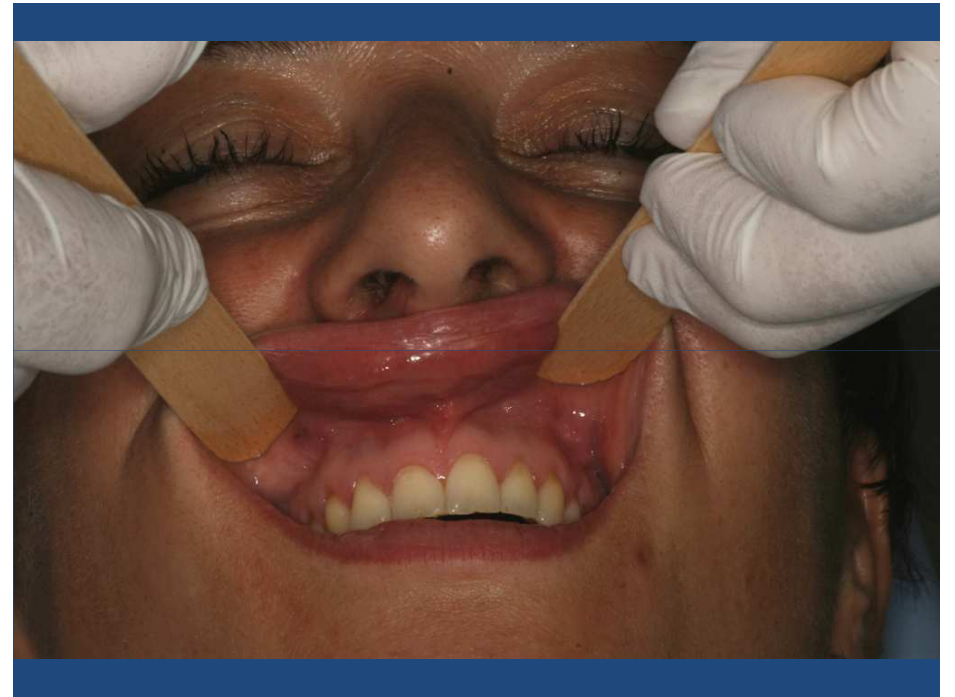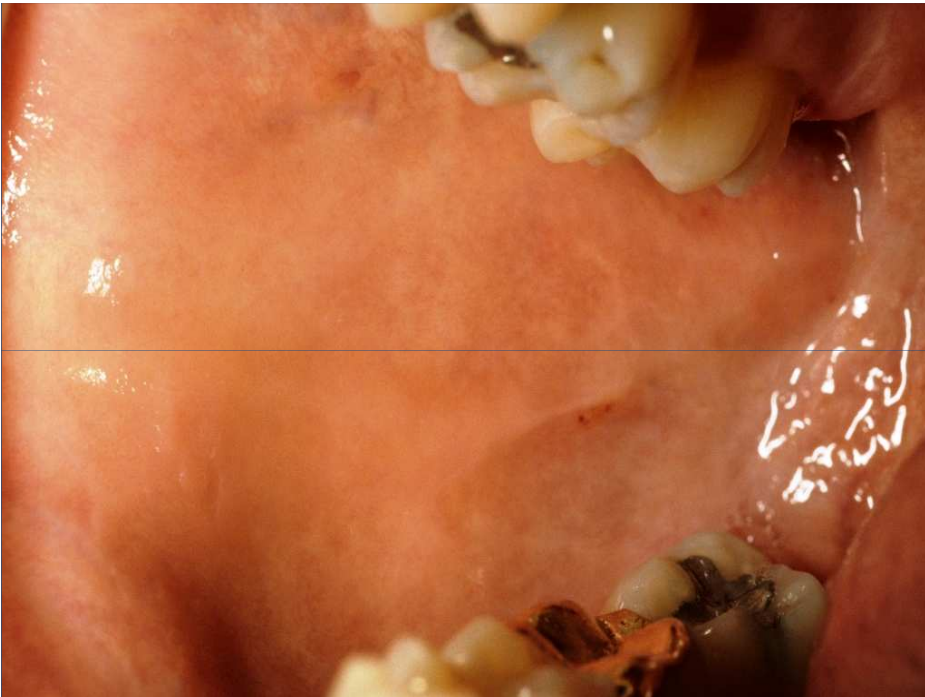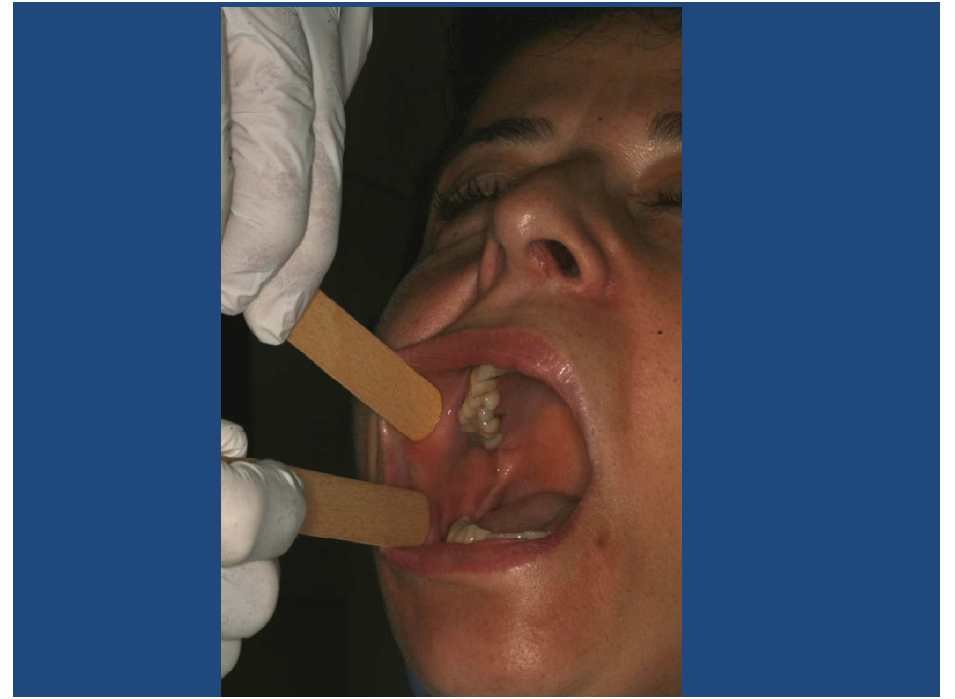


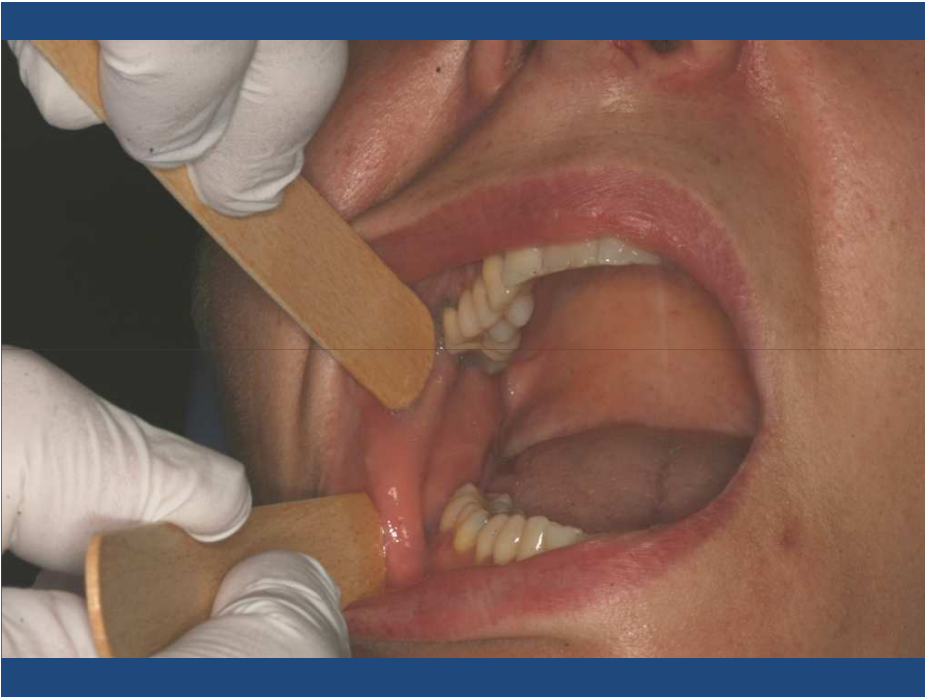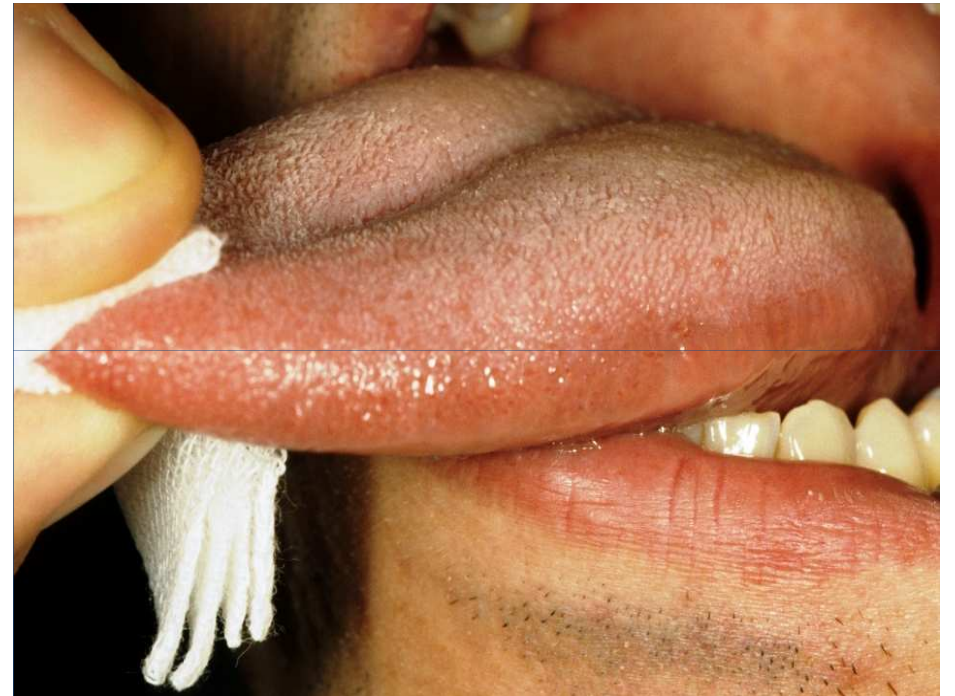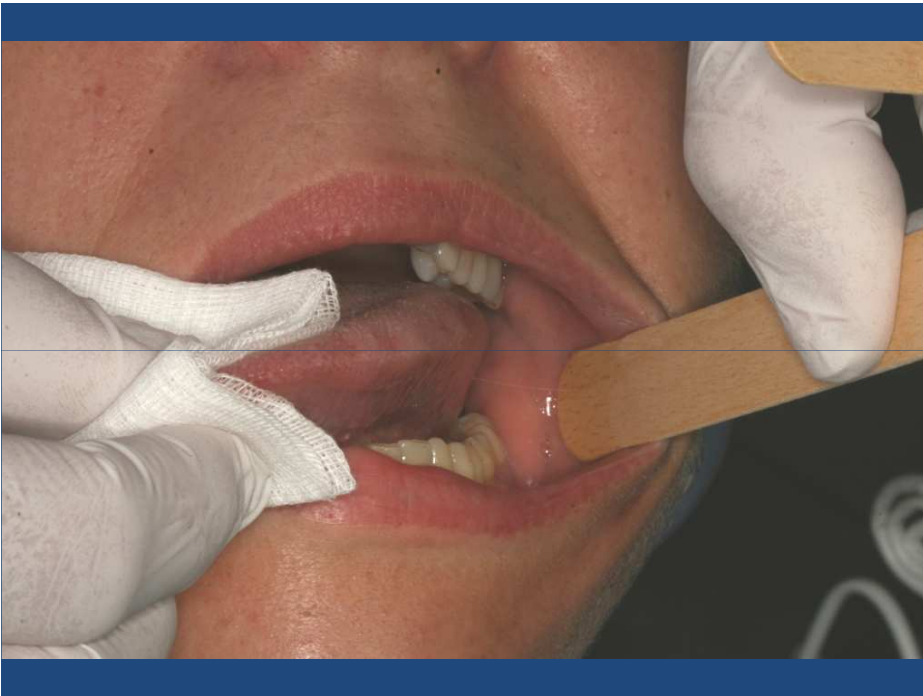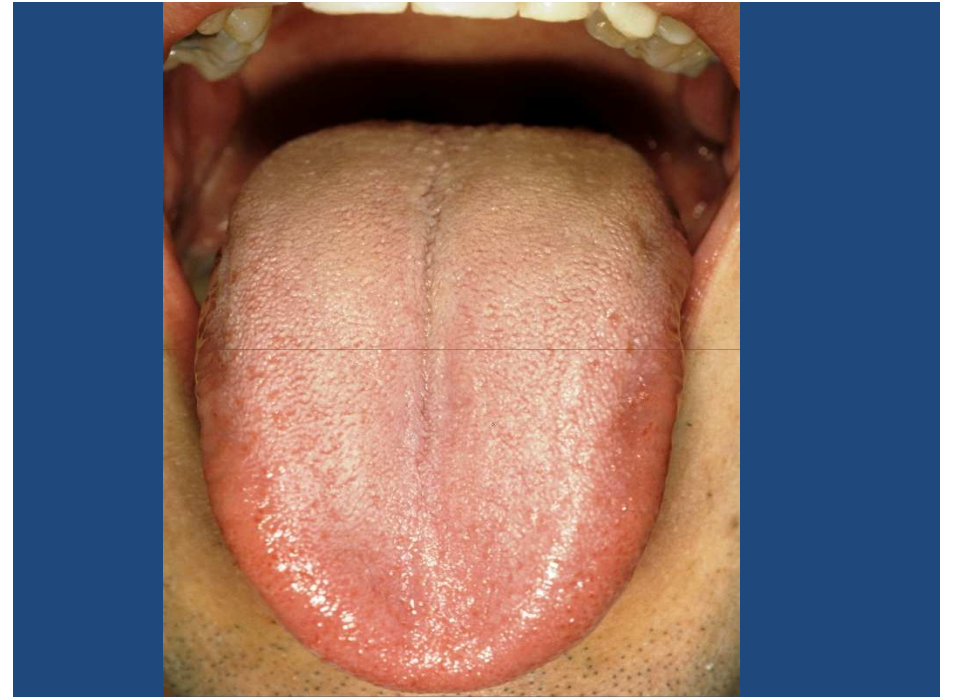
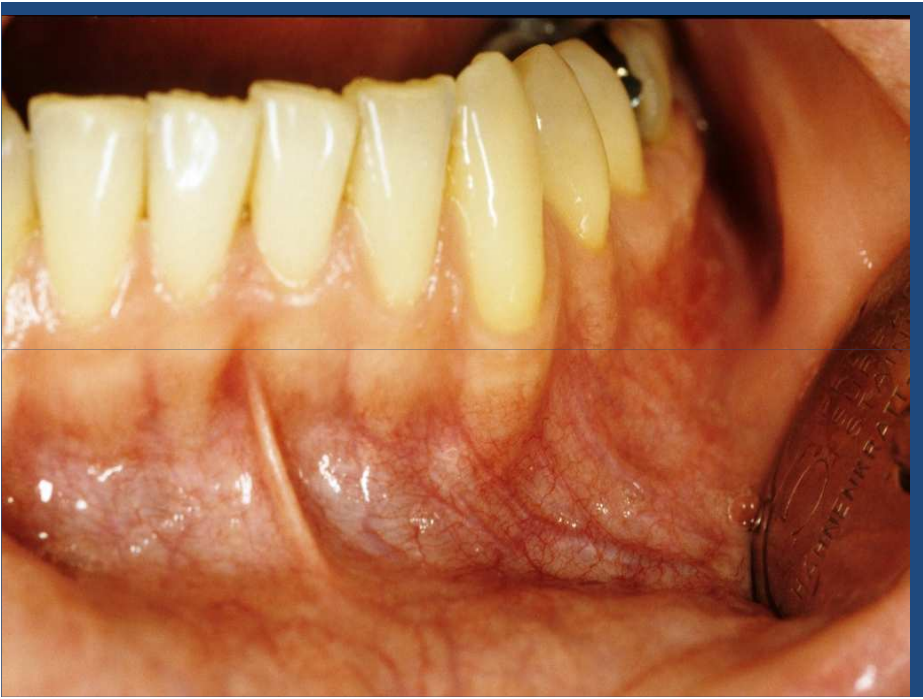## EXAMEN CLINIQUE

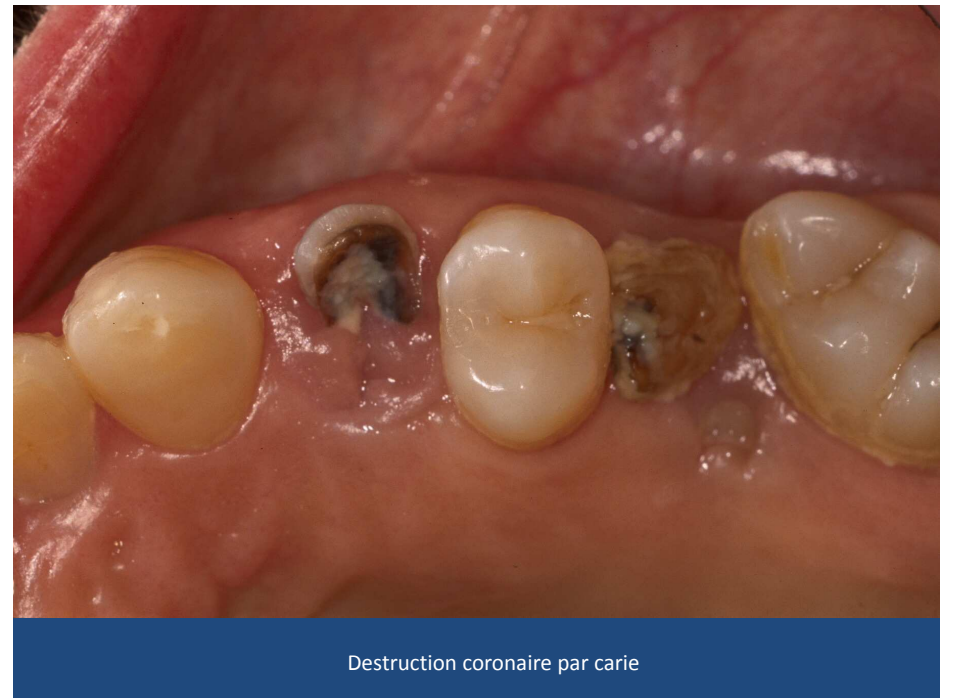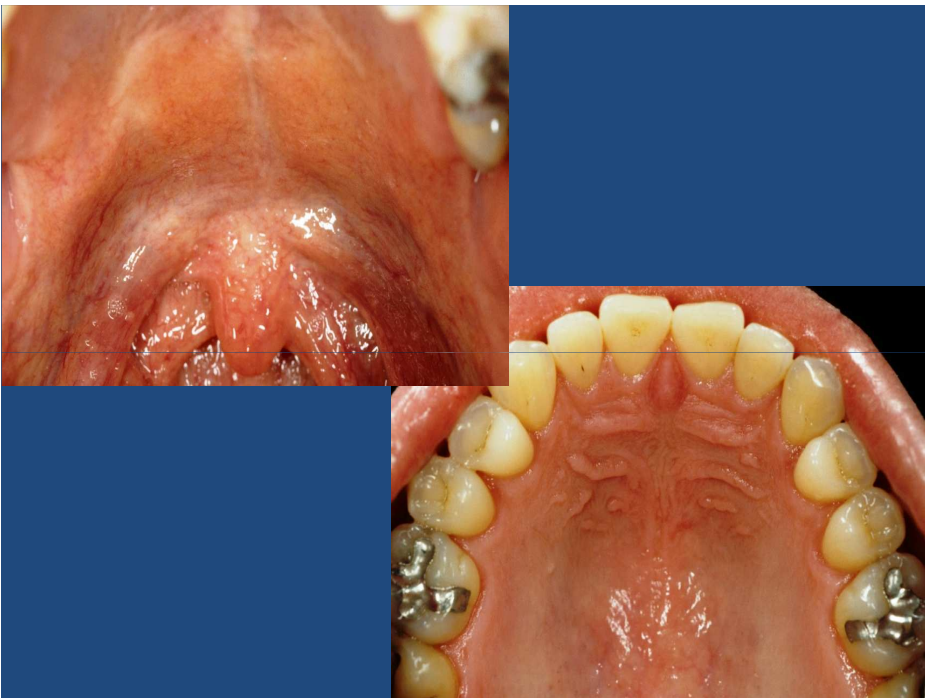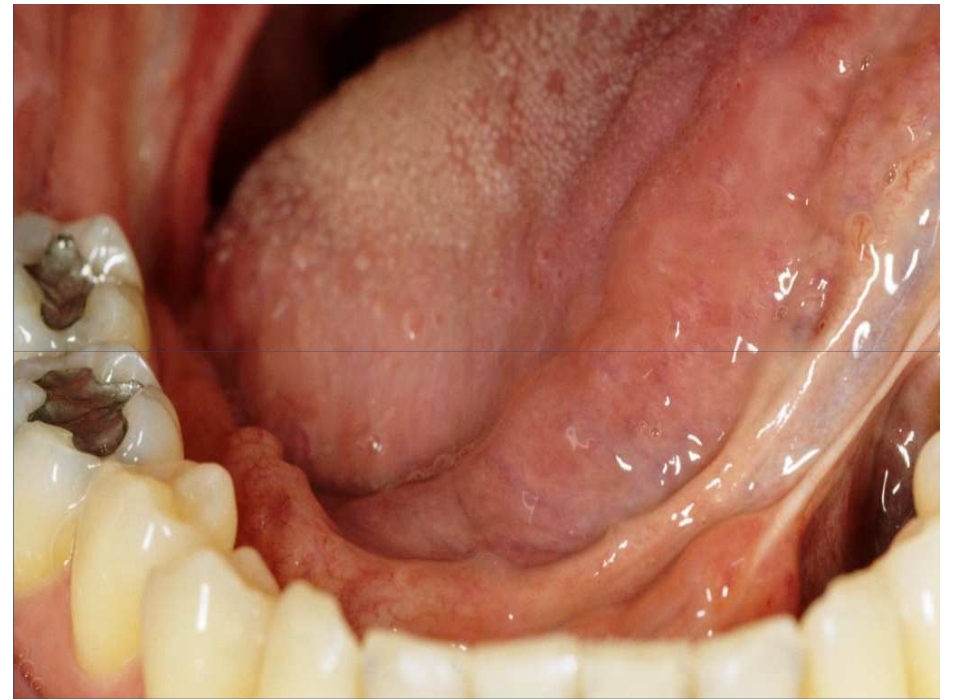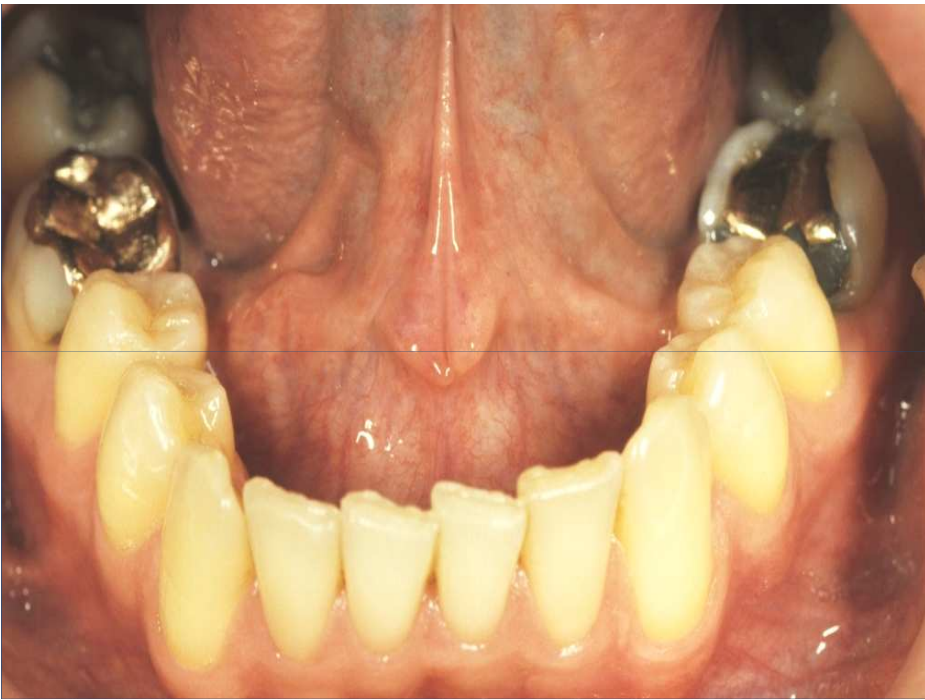o EXOBUCCAL

o ENDOBUCCAL

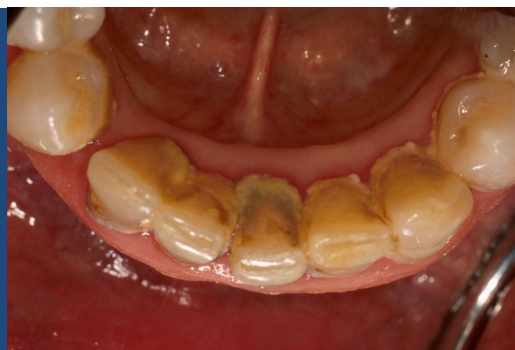




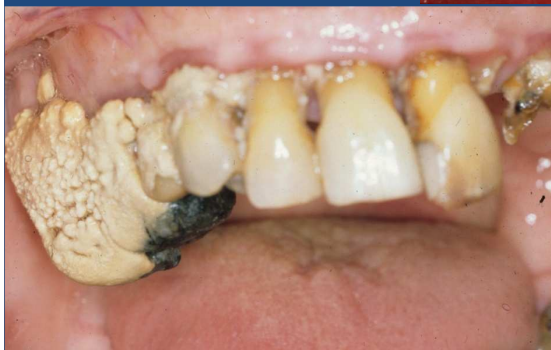


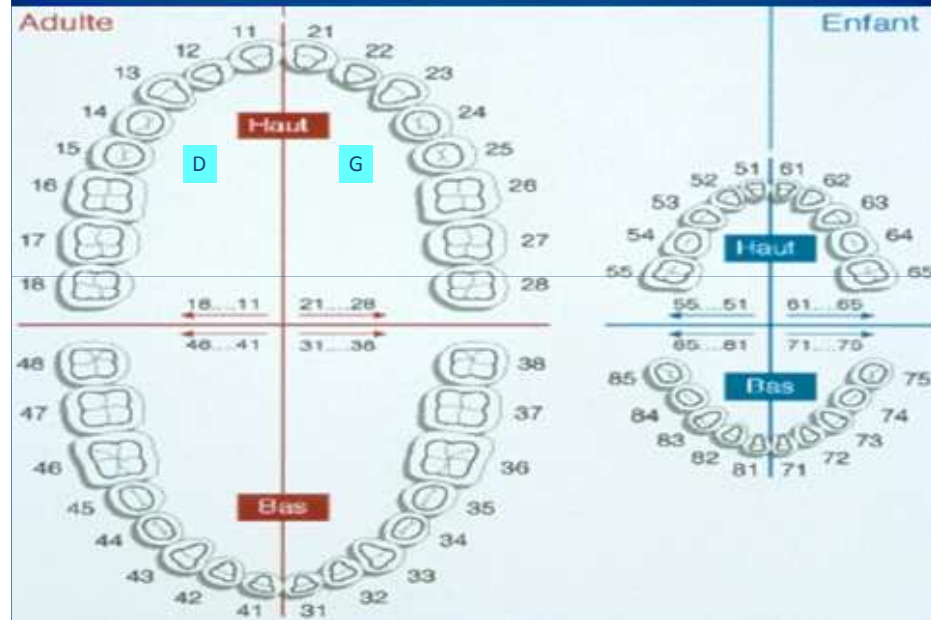
Tartre + gingivite



Tartre + parodontite

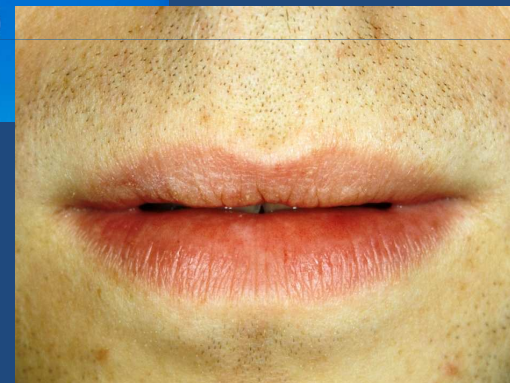


# Numérotation des dents



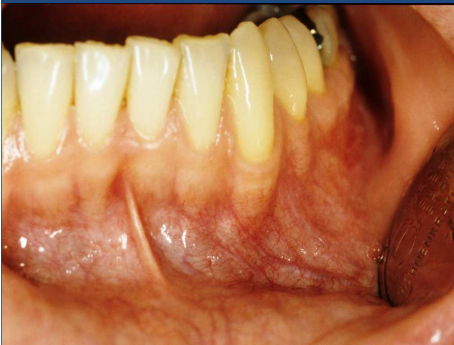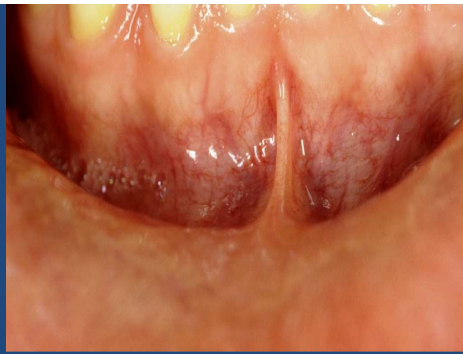## LEVRES

- LIGNE CUTANEO-MUQUEUSE
- DEMI MUQUEUSE
- LIGNE D'OCCLUSION
- MUQUEUSE LABIALE (Freins)
- COMMISSURES LABIALES



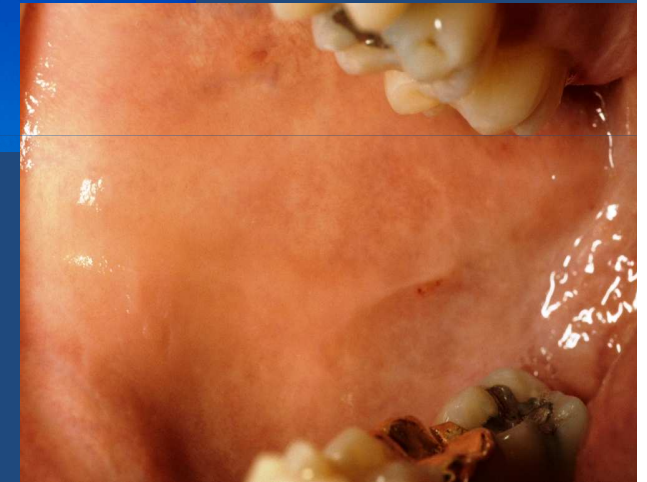## VESTIBULE BUCCAL

- FER A CHEVAL  
FACE EXT DES MAXILLAIRES
- VERSANT INTERNE  
⇒ CRETE ALVEOLAIRE
- VERSANT EXTERNE  
⇒ JOUE (en dehors)  
⇒ LEVRE (en avant)



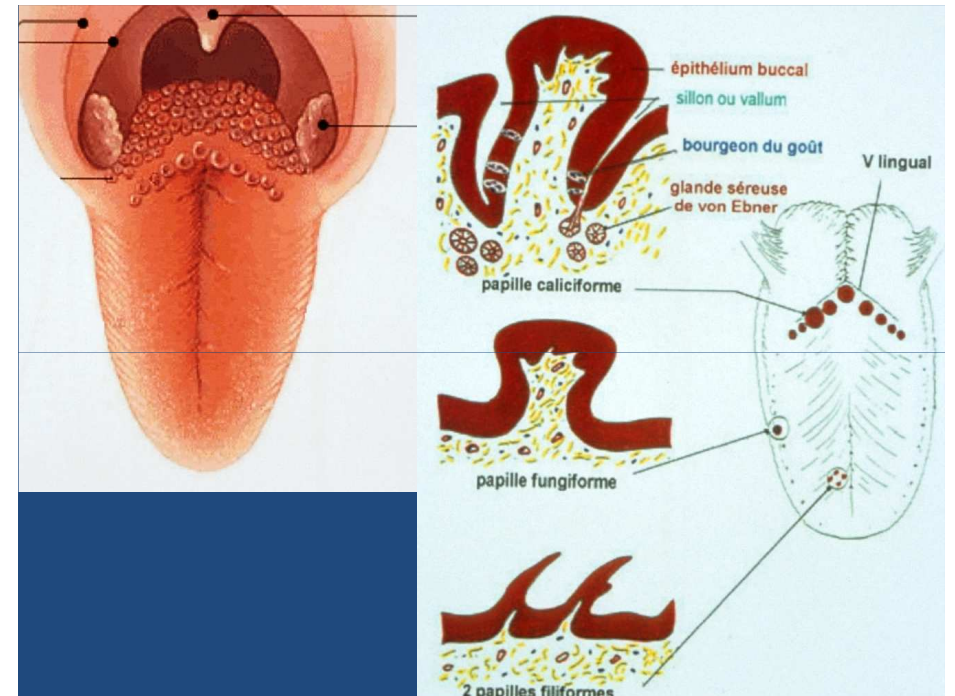
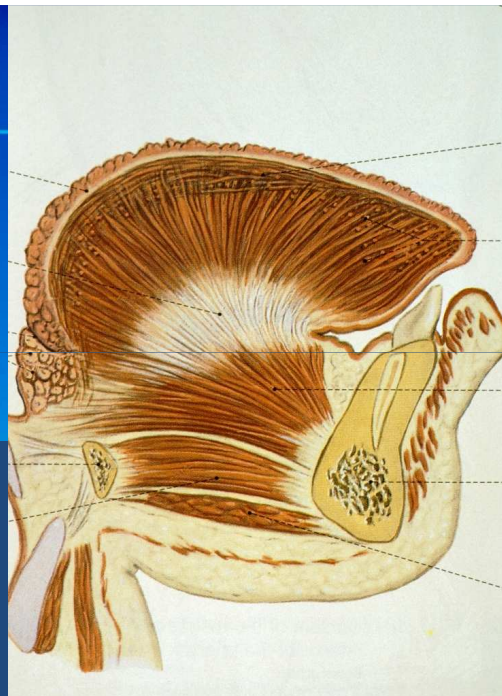
## FACE INERNE DE JOUE

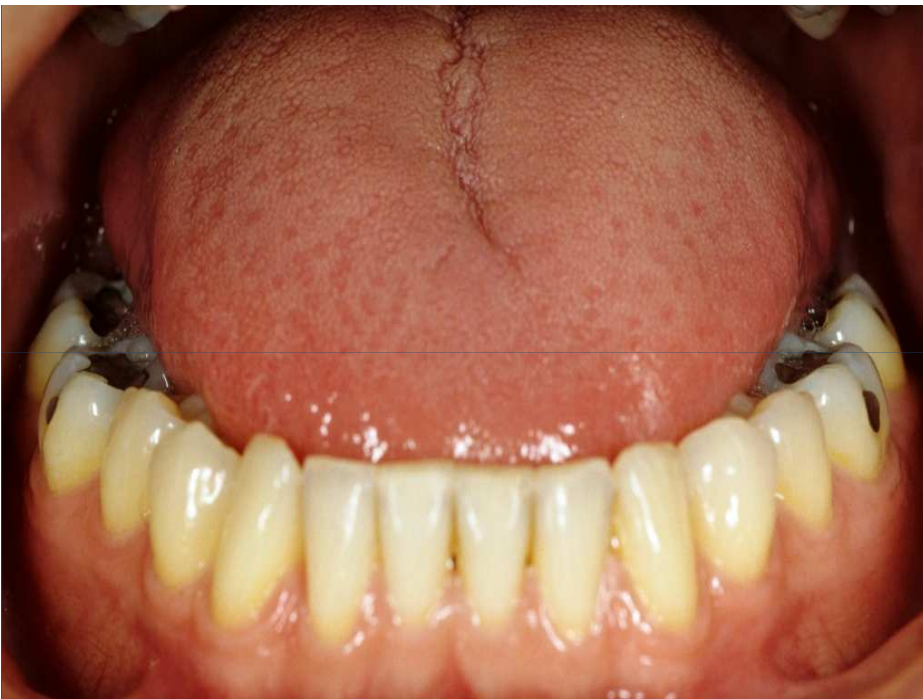
- COMMISSURE LABIALE
- COMISSURE INTER-MAXILLAIRE
- VESTIBULES BUCCAUX
- LIGNE D'OCCLUSION
- OSTIUM DU STENON



## LANGUE

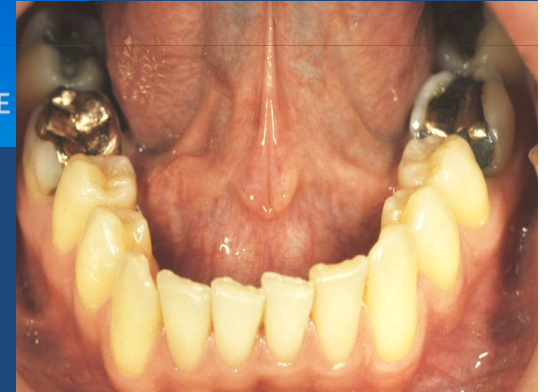- LANGUE MOBILE
  - Face dorsale ⇒ papilles / V
  - Face ventrale ⇒ frein
  - Bords
  - Pointe
- BASE DE LANGUE  
⇒ OROPHARYNX





## PLANCHER BUCCAL

- FER A CHEVAL
- LIMITE=FACE INT. MANDIBULE
- 1 PARTIE ANTERIEURE MEDIANE
  - ➔ WHARTONS
  - ➔ SUBLINGUALE
- 2 PARTIES LATERALES
  - ➔ SILLON AMYGDALO/GLOSSE



## PALAIS

- PALAIS DUR
  - Fibromuqueuse kératinisée
  - gl. salivaires accessoires
- VOILE
  - Mobile
  - Phonation/Déglutition

