Questions à poser:

- Avant le début
- Mode de démarrage
- Type des palpitations
- Fin de l'épisode
- Anamnese

Circumstances prior to the beginning of palpitations
Activity (rest, sleeping, during sport or normal exercise, change in posture, after exercise)
Position (supine or standing)
Predisposing factors (emotional stress, exercise, squatting or bending)
Onset of palpitations
Abrupt or slowly arising
Preceded by other symptoms (chest pain, dyspnoea, vertigo, fatigue, etc.)
Episode of palpitations
Type of palpitations (regular or not, rapid or not, permanent or not)
Associated symptoms (chest pain, syncope or near syncope, sweating, pulmonary oedema, anxiety, nausea, vomiting, etc.)
End of the episode
Abrupt or slowly decreasing, end or perpetuation of accompanying symptoms, duration, urination
Spontaneously or with vagal manoeuvres or drug administration
Background
Age at the first episode, number of previous episodes, frequency during the last year or month
Previous cardiac disease
Previous psychosomatic disorders
Previous systemic diseases
Previous thyroid dysfunction
Family history of cardiac disease, tachycardia or sudden cardiac death
Medications at the time of palpitations
Drug abuse (alcohol and/or others)
Electrolytes imbalance

Evaluation clinique

- L'évaluation clinique initiale devrait inclure une estimation éclairée de la probabilité d'une arythmie sous-jacente pertinente chez un patient présentant des palpitations

Table 1 Main causes of palpitations

Cardiac arrhythmias
Supraventricular/ventricular extrasystoles
Supraventricular/ventricular tachycardias
Bradyarrhythmias: severe sinus bradycardia, sinus pauses, second- and third-degree atrioventricular block
Anomalies in the functioning and/or programming of pacemakers and ICDs
Structural heart diseases
Mitral valve prolapse
Severe mitral regurgitation
Severe aortic regurgitation
Congenital heart diseases with significant shunt
Cardiomegaly and/or heart failure of various aetiologies
Hyperthrophic cardiomyopathy
Mechanical prosthetic valves
Psychosomatic disorders
Anxiety, panic attacks
Depression, somatization disorders
Systemic causes
Hyperthyroidism, hypoglycaemia, postmenopausal syndrome, fever, anaemia, pregnancy, hypovolaemia, orthostatic hypotension, postural orthostatic tachycardia syndrome, pheochromocytoma, arteriovenous fistula
Effects of medical and recreational drugs
Sympathicomimetic agents in pump inhalers, vasodilators, anticholinergics, hydralazine
Recent withdrawal of β-blockers
Alcohol, cocaine, heroin, amphetamines, caffeine, nicotine, cannabis, synthetic drugs
Weight reductions drugs

Palpitations: Clinical Correlates

Table 2 Types of palpitations and their clinical presentations

Type of palpitation	Subjective description	Heartbeat	Onset and termination	Trigger situations	Possible associated symptoms
Extrasystolic	'Skipping/missing a beat', 'sinking of the heart'	Irregular, interspersed with periods of normal heartbeat	Sudden	Rest	—
Tachycardiac	'Beating wings' in the chest	Regular or irregular, markedly accelerated	Sudden	Physical effort, cooling down	Syncope, dyspnoea, fatigue, chest pain
Anxiety-related	Anxiety, agitation	Regular, slightly accelerated	Gradual	Stress, Anxiety attacks	Tingling in the hands and face, lump in the throat, atypical chest pain, sighing dyspnoea
Pulsation	Heart pounding	Regular, normal frequency	Gradual	Physical effort	Asthenia

Table 4 Clinical features suggestive of palpitations of arrhythmic origin

Structural heart disease
Primary electrical heart disease
Abnormal ECG
Family history of sudden death
Advanced age
Tachycardiac palpitations
Palpitations associated with haemodynamic impairment

Raviele A et al, …Shah DC (document reviewer); Europace. 2011;13(7):920-34

ECG in the diagnosis of palpitations

Table 6 Electrocardiographic features recorded on standard electrocardiogram in absence of palpitations and suggestive of palpitations of arrhythmic origin

Ventricular pre-excitation
Atrioventricular reciprocating tachycardia
Atrial fibrillation
P-wave abnormalities, supraventricular premature beats, sinus bradycardia
Atrial fibrillation
Left ventricular hypertrophy
Ventricular tachycardia
Atrial fibrillation
Frequent ventricular premature beats
Ventricular tachycardia
Q wave, signs of arrhythmogenic right ventricular cardiomyopathy, Brugada syndrome or early repolarization syndrome
Ventricular tachycardia/fibrillation
Long or short QT
Polymorphic ventricular tachycardia
A-V block, tri- or bifascicular block
Torsades de pointes
Paroxysmal A-V block

ECG signs	Suspected disease
Corrected QT interval >0.46 s	Long QT syndrome
Corrected QT interval <0.32 s	Short QT syndrome
Right bundle branch block with coved type/saddle type ST segment elevation in the right precordial ECG leads (V1–V3) either spontaneous or provoked by flecainide or ajmaline	Brugada syndrome
ε-wave and/or T-wave inversion with QRS duration >110 ms in the right precordial ECG leads (V1–V3); ventricular ectopic beats with left bundle branch block and right-axis deviation morphology	Arrythmogenic right ventricular cardiomyopathy
High voltage in the precordial leads, Q wave, ST changes	Hypertrophic cardiomyopathy

Tachycardias and palpitations

Table 3 **Clinical characteristics of tachycardiac palpitations**

Type of arrhythmia	Heartbeat	Trigger situations	Associated symptoms	Vagal manoeuvres
AVRT, AVNRT	Sudden onset regular with periods of elevated heart rate	Physical effort, changes in posture	Polyuria, frog sign	Sudden interruption
Atrial fibrillation	Irregular with variable heart rate	Physical effort, cooling down, post meal, alcohol intake	Polyuria	Transitory reduction in heart rate
Atrial tachycardia and atrial Flutter	Regular (irregular if A-V conduction is variable) with elevated heart rate			Transitory reduction in heart rate
Ventricular tachycardias	Regular with elevated heart rate	Physical effort	Signs/symptoms of haemodynamic impairment	No effect

AVRT, atrio-ventricular reentrant tachycardia; AVNRT, atrio-ventricular node reentrant tachycardia; A-V, atrioventricular.

Raviele A et al, …Shah DC (document reviewer); Europace. 2011;13(7):920-34

Diagnostic Algorithm

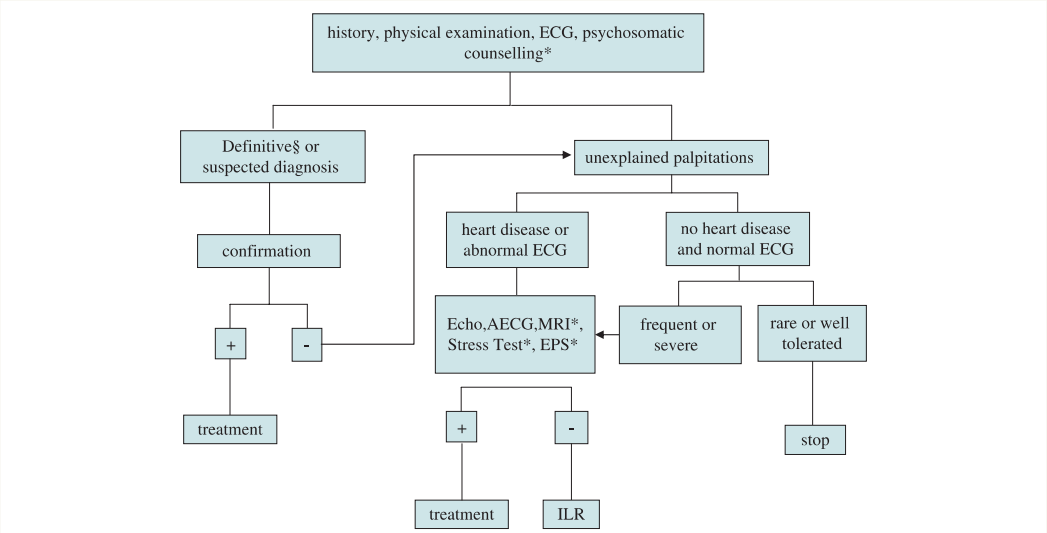

Figure 1 Diagnostic flow-chart of patients with palpitations. *Indicated only in selected cases; § refers to ECG–symptom correlation available. ECG, electrocardiogram (12-lead); Echo, echocardiography; AECG, ambulatory ECG; MRI, magnetic resonance imaging; EPS, electrophysiological study; ILR, implantable loop recorder.

Raviele A et al, …Shah DC (document reviewer); Europace. 2011;13(7):920-34

Bilan des palpitations, colloque MPR du 18.10.2017. Expert : Pr. Dipen Shah, Animateur : Dr. Olivia Braillard

When to hospitalise?

Table 11 Criteria for the hospitalization of patients with palpitations

Diagnostic purposes
Severe structural heart disease, suspected or ascertained
Primary electrical heart disease, suspected or ascertained
Family history of sudden death
Need to perform EPS, invasive investigations or in-hospital telemetric monitoring
Therapeutic purposes
Bradyarrhythmias requiring implantation of pacemaker
Pacemaker/ICD malfunction not rectifiable by reprogramming
Ventricular tachyarrhythmias requiring immediate interruption and/or ICD implantation or catheter ablation
Supraventricular tachycardias requiring interruption immediately or in a short time, or catheter ablation
Presence of heart failure or other symptoms of haemodynamic compromise
Severe structural heart diseases requiring surgery or interventional procedures
Severe systemic causes
Severe psychotic decompensation

Raviele A et al, …Shah DC (document reviewer); Europace. 2011;13(7):920-34